

# Concomitant Duodenal atresia and Hirschsprung's disease in Down's Syndrome - A rare variant

## Authors

1. Dr. Anshika Taiwade - Junior Resident, Department of Paediatrics, LN Medical College and JK Hospital, Bhopal, MP;
2. Dr. Nitin Vyas – Paediatric and Neonatal surgeon, Department of Paediatrics Surgery, LN Medical College and JK Hospital Bhopal;
3. Dr. Shweta Anand - Professor, Department of Paediatrics, LN Medical College and JK, Bhopal, MP;
4. Dr. Rashmi Vishwakarma - Associate Professor, Department of Paediatrics, LN Medical College and JK Hospital, Bhopal, MP;
5. Dr. Priyanka Shrivastava - Assistant Professor, Department of Paediatrics, LN Medical College and JK Hospital, Bhopal, MP

## CORRESPONDING AUTHOR

Name- Dr. Anshika Taiwade - Junior Resident,  
Department of Pediatrics, LN Medical College and JK Hospital, BHOPAL-462042, Madhya Pradesh  
Mobile Number : 7697551280, E-mail : anshika22.taiwade@gmail.com

## Abstract:

**Background:** This case report describe the association of Duodenal Atresia results from failed recanalization of the intestinal lumen during gestation with Hirschsprung's Disease also known as congenital aganglionic megacolon, results when the migration of neural crest cells from cecum to rectum is arrested prematurely, in patient with Down's syndrome. Duodenal Atresia and Hirschsprung's Disease are rare congenital anomalies, their co-existence with Down's syndrome is a Diagnostic and Management challenge.

## Clinical Description:

A two days-old Preterm (32+-2week), very low birth weight (1.4kg ) male baby with features suggestive of Down's Syndrome was referred to our hospital, already diagnosed antenatally Duodenal Atresia for surgery. Physical examination shows epigastric fullness and features suggestive of Down's Syndrome. An abdominal radiography showed the double-



bubble sign, characteristic for duodenal atresia, Gastrojejunostomy was done with prediagnosis of Duodenal Atresia. However, during the course of hospitalization Hirschsprung's Disease was suspected and the diagnosis was confirmed by biopsy. In this study, we described the case of duodenal atresia together with Hirschsprung's disease in a patient with Down Syndrome.

## Result and conclusion :

Association of Duodenal Atresia and Hirschsprung's Disease in a patient with Down's syndrome is possible, and should be considered for correct diagnosis and treatment.

**Key words:** Duodenal Atresia; Hirschsprung's Disease; Down's syndrome

### Introduction:

Trisomy 21 is the most common genetic etiology of moderate intellectual disability. The incidence of Down's syndrome in live births is approximately 1 in 733 (1). In addition to cognitive impairment, Down's syndrome is associated with congenital anomalies and characteristic dysmorphic features. Although there is variability in the clinical features, the constellation of phenotypic features is fairly consistent and permits clinical recognition of trisomy 21. Affected individuals are more prone to congenital heart defects (50%), Pulmonary complication, Central nervous system involvement, Gastrointestinal tract anomalies, Craniofacial, Cutaneous and Musculoskeletal involvement.(1) Gastrointestinal tract anomalies present in 12% of patient of Down Syndrome (2) which include Duodenal atresia, Annular pancreas, Tracheoesophageal fistula, Hirschsprung's disease, Imperforated anus, Neonatal cholestasis(1,2). Hirschsprung's disease occurs in approximately 1 in 5000 live births, 10% of all cases occur in children with Down's syndrome. Hirschsprung's disease, also known as congenital aganglionic megacolon, results when the migration of neural crest cells from cecum to rectum is arrested prematurely or when the ganglion cells undergo premature death(3). The association between Down's syndrome and Hirschsprung's disease may be linked to the Down's syndrome cell adhesion molecule gene on chromosome 21, overexpression of which leads to neural defects (4) The Duodenal atresia associated with Hirschsprung Disease in a patient with down syndrome is rare presentation (5,6). This case report describes the Duodenal atresia associated with Hirschsprung's Disease in a patient with Down's syndrome.

### Case Description:

A two days old, preterm (32+2 week), VLBW(1.4kg) male neonate was referred to our hospital with complaint of respiratory distress, bilious vomiting, inability to accept feed since birth. Physical examination showed epigastric fullness and features suggestive of Down's Syndrome. There was significant past history of death of previous sibling, also a known case of Down's syndrome at 18 months of age due to complex cyanotic congenital heart disease. Antenatal scan of current pregnancy confirmed features of Down's syndrome and impression of Duodenal Atresia. Patient was admitted in NICU, treatment started and necessary investigations sent. An abdominal radiography detected the Double-Bubble sign, classical for duodenal atresia (Figure 1), which was also confirmed by ultrasonography. An echocardiography revealed presence of small ASD. Baby was operated in view of Duodenal atresia, Exploratory Laparotomy with Gastrojejunostomy was performed. Intraoperatively, sigmoid colon was found to be dilated and filled with meconium which could not be squeezed out of rectum. Gradually feed started after confirming the patency in gastrografin meal (Figure 2) but Patient did not pass stools spontaneously and only defecates after syringing. With suspicion of Hirschsprung's disease, loop colostomy was done and biopsy taken from collapsed distal sigmoid colon (Figure 3). Post operatively stoma was functional and baby started passing stool. Biopsy revealed no ganglionic cell and was confirmatory for Hirschsprung's disease (figure 4). In spite of all the symptomatic and supportive care in NICU, baby could not be saved and succumbed after 51 days of life because of severe septicemia and DIC

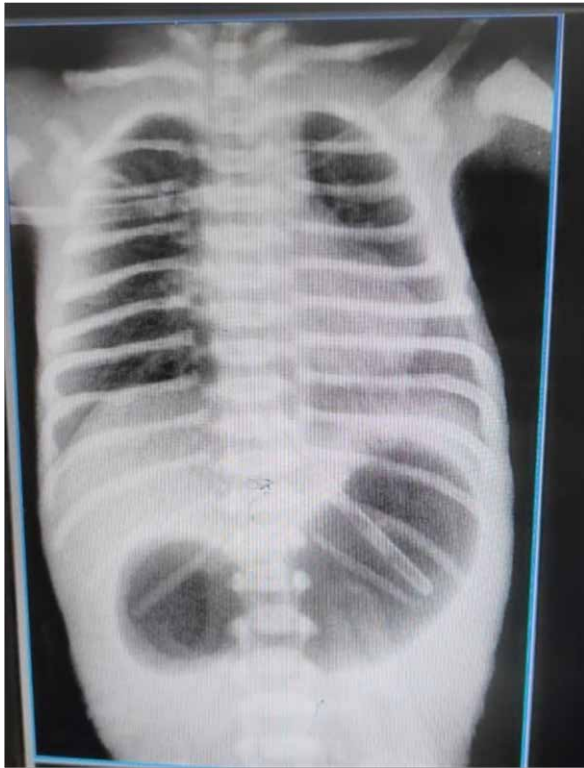

Figure 1

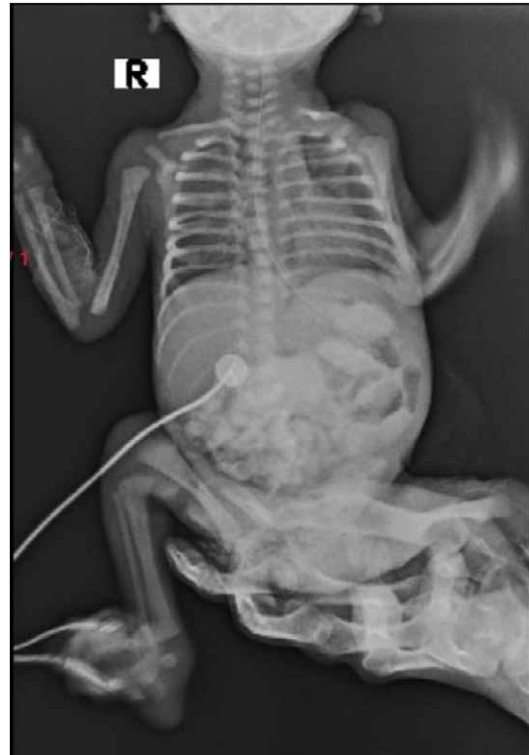

Figure 2

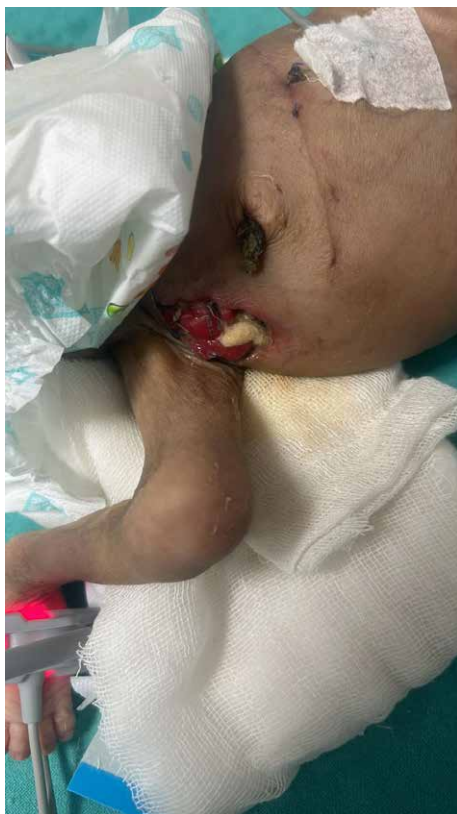

Figure 3

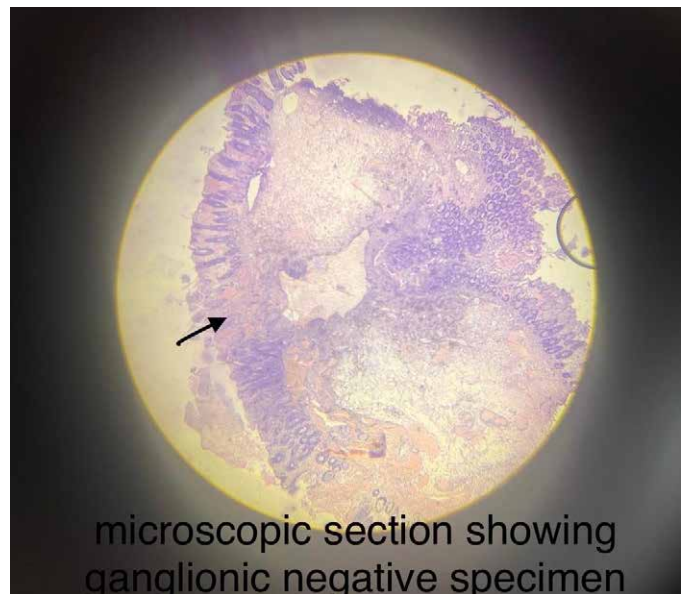


Figure 4

## **Discussion:**

Duodenal atresia results from failed recanalization of the intestinal lumen during gestation. Throughout the 4th and 5th week of normal fetal development, the duodenal mucosa exhibits rapid proliferation of epithelial cells. Persistence of these cells, which should degenerate after the 7th week of gestation, leads to occlusion of the lumen (atresia)(4). Approximately 30% to 40% of children with duodenal atresia have Down's syndrome. There is a 3% prevalence of congenital duodenal atresia among patients with trisomy 21/ Down's syndrome (7).

10% of all cases of Hirschsprung's disease occur in children with Down's syndrome. Hirschsprung's disease, also known as congenital aganglionic megacolon, results when the migration of neural crest cells from caecum to rectum is arrested prematurely or when the ganglion cells undergo premature death. This produces a distal intestinal segment that lacks both the Meissner's submucosal plexus and the Auerbach's myenteric plexus, termed aganglionosis. The association between Down's syndrome and Hirschsprung's disease may be linked to the Down's syndrome cell adhesion molecule gene on chromosome 21, overexpression of which leads to neural

defects in experimental models (4). Full thickness rectal biopsy is the "gold standard" for diagnosing Hirschsprung's disease. A contrast enema is most likely to aid in the diagnosis, classical findings are based on the presence of an abrupt narrow transition zone between the normal dilated proximal colon and a smaller-caliber obstructed distal aganglionic segment. Association of Duodenal atresia and Hirschsprung's disease in a patient of Down's syndrome has been reported in literature but exact incidence is unknown. In Down's Syndrome babies operated for duodenal atresia who is not defecating spontaneously, coexistence of Hirschsprung's disease should be kept in mind and should be managed aggressively.

## **Conclusion and Lesson Learnt:**

There is association of Duodenal atresia and Hirschsprung's disease in a newborn with Down's syndrome. So pediatrician and pediatric surgeon should regard this issue for correct diagnosis and treatment.

## **Financial Support and sponsorship**

Nil.

## **Conflicts of interest**

There are no conflicts of interest

## References-

1. Bredan Lee, Down syndrome and other abnormalities of chromosomal number, Nelson textbook of pediatrics volume 1, 21<sup>st</sup> edition.
2. Etiology of down syndrome, smith's recognizable patternof human malformation, 7<sup>th</sup> edition.
3. Congenital abnormalities of gastrointestinal tract,Robin and Cotron pathological basis of disease,10<sup>th</sup> edition.
4. Asim Maqbool and Chris A Liacouras, Congenital aganglionic megacolon,Nelson textbook of pediatrics volume 2, 21<sup>st</sup> edition.
5. Levy J. The gastrointestinal tract in Down syndrome. Prog Clin Biol Res;373:245-56.
6. Surana R, Quinn, FMJ,Puri,P. Hirschsprung's disease in association with trisomy 21 and duodenal obstruction. Pediatr Surg Int ;9, 366-367.
7. Asim Maqbool and chris A Liacouras,Duodenal obstruction, Nelson textbook of pediatrics volume 2, 21<sup>st</sup> edition.
8. Tamer Sekmenli, Mustafa Koplay, Ulas Alabalik, Ali Sami Kivrak, case report on Duodenal Atresia and Hirschsprung Disease in a Patient with Down Syndrome, European Journal of General Medicine.